



NHS MEDICAL POLICY

Upper Eyelid Blepharoplasty, Blepharoptosis or Brow Ptosis Repair Procedure 2014-005

Upper eyelid blepharoplasty, upper eyelid blepharoptosis repair or brow ptosis repair may be indicated when ALL the following are present:

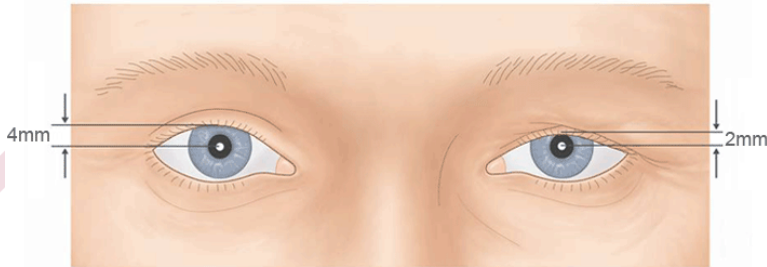
1	<p>Provider's clinical records which include ALL of the following:</p> <ul style="list-style-type: none"> • History of the medical condition(s) requiring surgical intervention • Documented interference with vision or visual field related activities. • Preoperative ophthalmologic examination • Margin reflex distance (MRD) below or equal to 2.0 mm. <p>Definition: (MRD is a measurement from the corneal light reflex to the upper eyelid margin with the brows relaxed. See Appendix A Margin Reflex Distance Measurement.)</p>
2	<p>Visual field testing with eyelids taped and un-taped must document interference with central vision by a superior visual field loss of at least 12 degrees or at least 24% impairment.</p> <p>Definition: (Central vision is defined as the central 40 degrees of vision or 20 degrees above and below fixation.)</p>
3	<p>Photographs or copies of adequate quality to visualize both eyes, eyelids and eyelashes must be taken in the frontal, straight-ahead position and down-gaze position. The date taken, and patient identification must be documented with the photographs.</p>
4	<p>Photos must demonstrate at least ONE finding that is consistent with the provider's diagnosis:</p> <ul style="list-style-type: none"> • An abnormally low upper eyelid position consistent with ptosis • Redundant skin resting on the eyelashes or over the eyelid margin consistent with dermatochalasis or blepharochalasis <p>Definition: (Ptosis, or blepharoptosis, is a downward displacement of the upper eyelid margin, which can result in partial or complete obstruction of the patient's visual field. Dermatochalasis is redundant or excess eyelid skin and can also involve underlying muscle, connective tissue, and fat. Blepharochalasis causes recurrent bouts of upper eyelid edema with thinning, stretching, and</p>

wrinkling of the involved skin. This can result in upper eyelid skin redundancy. This excess skin can weigh down the upper lid causing the normal upper lid margin to obscure vision. Alternatively, excess skin can hang over the edge of the lid margin and eyelashes, directly obscuring vision. The surgical correction is to remove excess skin and tissue from the upper lid.)

NOTE:

Use MCG A-0195 for the following conditions: ectropion, entropion and exposure keratitis.

Appendix A: Margin Reflex Distance Measurement



Herring's effect

The presence of Herring's effect may meet one of these criteria: margin reflex distance below 2.0 mm or downgaze palpebral fissure height of 1 mm or less. Herring's law is one of equal innervation to both upper eyelids and is considered in the documentation to perform bilateral ptosis repair in which the position of one upper eyelid has marginal criteria and the other eyelid has good supportive documentation for ptosis surgery. In these cases, the surgeon can lift the more ptotic lid with tape or instillation of Phenylephrine drops into the superior fornix. If the less ptotic lid then drops downward according to Herring's law to the point of an MRD of 2.0 mm or less or a palpebral fissure width on down-gaze of 1 mm or less, then the less ptotic lid would be considered for surgical correction.

SOURCES

1. American Academy of Ophthalmology. Functional Indications for Upper and Lower Eyelid Blepharoplasty. Ophthalmic Technology Assessment. Ophthalmology April 1995. 102: 693-695.
2. American Society of Plastic and Reconstructive Surgeons. Position paper: Blepharoplasty and eyelid reconstruction. Recommended Criteria for Third-Party Payer Coverage. October 1995. Plasticsurgery.org was accessed on Sept 9, 2019: Practice Parameter, revised Feb 19, 2010
3. Bellinvia G, et al. Upper lid blepharoplasty, eyebrow ptosis, and lateral hooding. Aesthet Surg J. 2013 Jan;33(1):24-30
4. Cahill KV; Burns JA; Weber PA. The effect of blepharoptosis on the field of vision. Ophthal Plast Reconstr Surg . 1987; 3(3): 121-5.
5. Cahill KV, et al. Functional indications for upper eyelid ptosis and blepharoplasty surgery: a report by the American Academy of Ophthalmology. Ophthalmology 2011;118(12):2510-7.
6. Cetinkaya A, Brannan PA. Ptosis repair options and algorithm. Current Opinion in Ophthalmology 2008;19(5):428-34.
7. Custer PL. Blepharoptosis. In: Yanoff M, Duker JS, editors. Ophthalmology. 3rd ed. St. Louis, MO: Mosby Elsevier; 2009:1397-403.
8. DeAngelis DD, Carter SR, Seiff Sr. Dermatochalasis. Int Ophthalmol Clin 2002; 42(2):89-101.

9. Edmonson BC, Wulc AE. Ptosis evaluation and management. Otolaryngologic Clinics of North America 2005;38(5):921-46.
10. Friedland JA, Lalonde DH, Rohrich RJ. An evidence-based approach to blepharoplasty. Plastic and Reconstructive Surgery 2010;126(6):2222-9.
11. Meyer DR; Lindberg JV; Powell SR. Quantifying the superior visual field loss associated with ptosis. Arch Ophthalmol 1989;107:840-843.
12. Parikh S, Most SP. Rejuvenation of the upper eyelid. Facial Plastic Surgery Clinics of North America 2010;18(3):427-33.
13. Small RG; Sabates NR; Burrows D. The measurement and definition of ptosis. Ophthal Plast Reconstr Surg. 1989;5(3):171-5
14. Trussler AP, Rohrich RJ. MOC-PSSM CME article: Blepharoplasty. Plastic and Reconstructive Surgery 2008;121(1 Suppl):1-10.
15. Milliman Care Guidelines, 24th edition, A-0195, accessed March 3, 2020.

CODE REFERENCE (This may not be a comprehensive list of codes to apply to this policy.)

CPT®: 15820, 15821, 15822, 15823, 67900, 67904, 67914, 67915, 67916, 67917, 67921, 67922, 67923, 67924, 67950

POLICY HISTORY/REVISION INFORMATION

Date	Action/Description
12/18/2014	Updated to add brow ptosis repair and codes, approved in UM committee
12/16/2015	Annual review – no changes
12/14/2016	Annual review – no changes
09/12/2017	Updated to add: below or equal to 2.0 mm
06/13/2018	Line 1: Removed "Treating physician's plan of care for all of the proposed procedure(s), which must include the expected outcome for improvement of vision"
09/12/18	Reviewed no changes
09/12/2019	Under SOURCES: added to Line 2 Plasticsurgery.org was accessed on Sept 9, 2019: Practice Parameter, revised Feb 19, 2010 - Added line 3 3. Bellinva G, et al. Upper lid blepharoplasty, eyebrow ptosis, and lateral hooding. Aesthet Surg J. 2013 Jan;33(1):24-30 - Added Line 16 Milliman Care Guidelines, 23rd (current) edition, A-0195, accessed Sep 9, 2019.
03/12/2020	Changes to line items 1-4 and adding definitions; page 2 adding Note: Use MCG A-0196 for the following conditions: cctropion, entropion and exposure keratitis; Appendix A: Margin Reflex Distance Measurement and under Sources added Line 15
03/12/2021	Annual review – no changes
03/28/2022	Annual review – no changes
02/22/2023	Annual review – no changes
02/20/2024	Annual review – no changes